



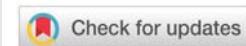
Received: 06 April, 2020

Accepted: 26 June, 2020

Published: 27 June, 2020

***Corresponding author:** Giulio Perrotta, Psychologist sp.ed Strategic Psychotherapist, Forensic Criminologist, Jurist sp.ing SSPL, Lecturer, Essayist, Italy, E-mail: giuliosr1984@hotmail.it

<https://www.peertechz.com>



Review Article

Gender dysphoria: Definitions, classifications, neurobiological profiles and clinical treatments

Giulio Perrotta*

Psychologist sp.ed Strategic Psychotherapist, Forensic Criminologist, Jurist sp.ing SSPL, Lecturer, Essayist, Italy

Abstract

This work focuses on the theme of gender dysphoria and in particular on clinical, psychopathological and anatomy physiological elements, to understand if there are substantial elements to suppose the neurophysiological diversity between a dysphoric people and a not-dysphoric people, and therefore understand if these are the differences which cause the dysphoric condition or whether the dysphoric condition shapes the anatomy and physiology of the brain by inducing changes.

Contents of the manuscript

Introduction, definitions and classifications

“*Gender dysphoria*” is the new definition of “gender identity disorder” contained in previous versions of DSM-V, the diagnostic and statistical manual of mental disorders, intended as a strong and persistent identification with the opposite sex, associated with anxiety, depression, irritability, malaise, a sense of not-belonging and an intense desire to live as a gender other than the sex assigned to birth. People with gender dysphoria feel victims of a biological accident and therefore live their condition as if they were cruelly imprisoned in a body incompatible with their subjective gender identity.

The first definition of gender dysphoria was introduced by Laub and Fisk in 1971 and was immediately understood as a mental disorder, exactly as homosexuality was. In particular, in DSM-IV (2000) there was a clear distinction between “dysphoric” (still called sexual identity disorder) and “transsexual”: the second was simply a dysphoric that did not present further associated psychopathologies. Also in this version of the diagnostic manual, the specific criteria that identified the “gender identity disorder” were the following:

1. The people identify himself intensely and persistently

with individuals of the opposite sex to the biological one;

2. This identification must not simply be a desire for some presumed cultural advantage deriving from belonging to the opposite sex (to the biological one);
3. There must be evidence of a condition of persistent malaise or extraneousness regarding one’s biological sex;
4. Strong desire to belong to the opposite gender;
5. The individual must not exhibit an intersex condition (e.g. androgen insensitivity syndrome or congenital adrenal hyperplasia);
6. Strong desire to be treated as a member of the opposite gender;
7. There must be clinically significant distress or impairment in the social, work, and interpersonal relationships.

DSM-5 (2013) renames the disorder in “gender dysphoria”, reassigning it to a category of its own, no longer belonging to the group of sexual disorders, and identifying it with the following description: persistent suffering experienced by the

individual whose assigned sex at birth it does not coincide with the perceived gender. The diagnostic criteria also change, of which at least two must be present for not less than six months:

1. Marked inconsistency between experienced gender and primary / secondary sexual characteristics;
2. Strong desire to get rid of their primary and / or secondary sexual characteristics due to the marked inconsistency with the experienced gender;
3. Strong desire for the sexual characteristics of the opposite gender;
4. Strong desire to belong to the opposite gender;
5. Strong desire to be treated as a member of the opposite gender;
6. Strong conviction of having typical feelings and reactions of the opposite kind.

The condition must be associated with clinically significant suffering or impaired functioning in the social, occupational, or other important areas.

In addition to the characteristics required for all ages, children (who usually begin to experience the first symptoms around 2–6 years) must have ≥ 6 of the following:

- 1) A strong desire to belong or the urge to be of another kind (or some other kind);
- 2) A strong preference in dressing in typical clothes of the opposite sex and, in girls, resistance to the use of typically female clothing;
- 3) A strong preference for the exchange of sexual roles when playing;
- 4) A strong preference for toys, games, and activities typical of the other genre;
- 5) A strong preference for other playmates;
- 6) A strong refusal of toys, games, and activities typical of the genre that corresponds to the sex of birth;
- 7) A strong aversion towards their anatomy;
- 8) A strong desire towards primary and / or secondary sexual characteristics which correspond to the perceived gender identity.

Identification with the opposite sex must not represent a pure desire to obtain the cultural advantages of belonging to the opposite sex as they are perceived. For example, a boy who says he wants to be a girl so he can get the same special treatment as his little sister probably doesn't have gender dysphoria.

A few years later, in 2018, the ICD-11, the international classification of diseases of the World Health Organization, also declassifies "gender dysphoria", going from "mental disorder" to "gender inconsistency" (practically, sexual

health disorder without psychopathological traits). To better understand the reason that prompted the Commission to evaluate this structural change we must necessarily analyze some theoretical differences:

"*Biological sex*" is the biological status: "male" (testicles and penis), "female" (vagina, uterus, and ovaries), "intersex / hermaphrodite" (chromosomal sex is in contradiction with phenotypic sex or phenotypic sex cannot be classified as male or female or has ambiguous genital organs);

"*Sexual identity (or orientation)*" is the sexual choice in which the person's action is oriented and for which he feels physical attraction: "heterosexual", "homosexual", "bisexual";

"*Identity (or orientation) of gender*" is the subjective knowledge of belonging to a certain sex, it is, therefore, how the person sees and feels: "male", "female", "transgender" (he or she who does not recognize herself in the sex of birth but who has not gone through a transition path for the reassignment of sex), "transgender" (he -MtF- or she -FtM- who does not recognize herself in the sex of birth but who is facing or has undergone a transition path for the reassignment of sex) "genderqueer or not-binary gender" (does not recognize himself in any of the two typical male-female genders and rejects the binary sexual roles assigned since birth, thus adopting a personal role identity and felt as proper, which goes beyond the role of gender-stereotyped and understood as historical-cultural construct);

"*Gender role*" is the social, public and objective expression of gender identity and includes everything that people say and do to indicate to themselves and others the degree to which they identify with gender membership: "male", "female", "transvestite".

"Sex" therefore refers to a person's biological and physiological properties, while "gender" refers to the personal psychological identification of the binary gender for men and women, to the social roles assigned and to social and cultural learning processes. On this assumption, gender dysphoria is independent of sexual orientation and should not be confused with it: transgender women and men can have any sexual and sentimental orientation, for example they can be heterosexual, homosexual, or bisexual.

The result of an inconsistency between the psychological gender and biological sex determines in the transgender individual a continuous search for similarity to the preferred sex and the strong identification with the opposite gender in combination with the prevalence, in most cultures, of a system of binary gender, as well as poor social acceptance, causes serious psychological stress in transgenders. Psychiatric disorders appear high in this patient population when compared with the general population, with a spike in anxiety and mood disorders. However, transgenderism, according to the modern DSM-V, is not directly associated with psychiatric disorders, but it is assumed that these problems are the result of strong stressful social experiences and therefore transgenders who suffer from their condition can also receive the diagnosis

of “Gender dysphoria”. Being gender is not an automatic condition for assigning a dysphoric diagnosis.

Anatomy and neurobiological profiles

From a biological point of view there are no particular physical anomalies, as well as chromosomal aberrations that can be directly associated with transgenderism, although some studies trace hypotheses related to a form of hereditary transgenderism. Indeed, some studies suggest that the development of transgenderism is related to biological mechanisms, such as genetic factors or prenatal exposure to sex hormones, as well as environmental factors such as parental care and support practices.

If in man the volume of the brain is 1260 cc and the volume of cerebrospinal fluid and ventricles is greater, with a higher percentage of the white matter, in women the volume of the brain is 1130 cc and the higher the percentage of gray matter. Furthermore, if in man the amygdala has a greater volume than that of the woman, with a reduction in the volume of the frontal and temporal lobes, in the woman the volume of the hippocampus is instead greater, with a significant reduction in advanced age (however) of the hippocampus and parietal lobes. Furthermore, cerebral blood flow is higher in women than in men (both in rest condition and during cognitive activity), with a higher glucose metabolism especially in the orbit-frontal area, as well as cortical values are higher muscarinic acetylcholine, GABA, serotonin, and dopamine. Intellectual capacity in men correlates with the volume of gray matter in the frontal and parietal lobes, while in women in the frontal lobe and the Broca area. If then estrogens increase the excitability of hippocampal cells while preserving women from any damage caused by chronic stress, in men this condition is missing, causing a dendritic CA3 degeneration and a hippocampal hypotrophy.

During pregnancy, the fetal brain develops in a male brain under the influence of testosterone, and in a female brain in the absence of this hormone. However, sexual differentiation of the brain occurs much later than that of the genitals. These two processes can be influenced independently if they develop in opposite directions as occurs precisely in transgenderism. Therefore, transgenderism is seen as the result of a discrepancy between the brain and genital sexual differentiation caused by hormonal or genetic deviation.

Studies conducted on twins with transgender children are quite scarce, as are very low prevalence rates. Therefore even if the evidence for genetic influences on transgenderity is limited, the available data indicate a possible hereditary component. A study conducted by Gomez - Gil, et al. On 995 transsexuals, suggests that not-twin brothers also had a higher risk of being transgender than the general population. The risk appears to be higher for siblings than for sisters, that is, for siblings of MtF transgenders, compared to FtM transgenders.

A genetic aberration of the hormonal state could be the result of an abnormal prenatal exposure to sex hormones, for example due to an altered sensitivity or by alteration of the receptor function of the sex hormones or by alteration of the

synthesis processes of sex steroids. A rough indicator for the measurement of prenatal exposure to testosterone is the digit ratio or 2D: 4D ratio, which indicates the relationship between the length of the index finger and the ring finger in the right hand; if the index finger is shorter than the ring finger, the 2D / 4D ratio gives rise to fewer than one, and would indicate a high exposure to testosterone in the uterus during the fetal period. The Digit ratio is therefore an indicator of sexual dimorphism; concerning the length of the ring finger, a long index finger is considered to be a “more feminine” hand, a shorter index finger instead of a “more masculine” hand. By applying this measurement in the study of transgenderism, the results support the assumption of prenatal exposure to testosterone as the etiological factor of transgenderism, particularly in the MtF form.

Data from women with congenital adrenal hyperplasia, a metabolic disorder characterized by a deficit in the production of sexual steroids, indicates an antenatal androgenization that is related to masculine infantile behavior.

However, no association was found between gender confusion or subsequent dysphoria. In this sense, gender identity does not seem to be determined by an androgenic prenatal exposure, although several clinical factors can strongly influence this hypothesis, such as polymorphisms in *Erβ* genes, androgenic receptors, cloacal exstrophy, intake phenobarbital or during pregnancy, Turner’s syndrome and congenital adrenal hyperplasia.

There are few studies on the relationship between transgenderism and the genes involved in the synthesis of sex steroids. Two studies suggest a link between the *CYP17* gene polymorphism and transgenderism. *CYP17* is associated with an increase in serum and plasma levels of estradiol, progesterone, and testosterone. Bentz, et al. Have shown that damage to the female allelic distribution of the *CYP17* gene, specifically *CYP17 T-34C*, is associated with forms of FtM transgenderism and not with those of MtF. More recent data suggest an association with the *A2* allelic frequency of the *CYP 17 MspA1* polymorphism, as an allelic frequency that appears to be sex-dependent in transgenders, but not in the general population, and with a higher frequency in FtM cases, compared to that MTF. The available data, therefore, suggest that transgenderism is attributable to biological factors, but that psychosocial factors mediate its genesis.

Recent literature has instead highlighted how there are obvious differences between the sexes in brain morphometry, although recent studies by Swabb [1-45] and Koutkerov [45-97], have shown that sexual dimorphism is detectable in the hypothalamus, and in particular in the nucleus of the preoptic area, in the interstitial nucleus and the intermediary nucleus. Other obvious differences, however, exist both concerning the total brain volume and in the dimorphic-sexual structures. The results showed that the total brain volume is greater in men than in women. However, women have a greater proportion of gray matter, and men have a greater proportion of white matter. These results prompted researchers to ask whether the psychological identification with the other gender in

transgenderism can also be reflected in the brain anatomy. And in fact, both post-mortem anatomical analyzes as well as in vivo neuroimaging studies revealed structural differences in different brain areas, comparing transgender individuals and control groups, particularly in those related to sexual dimorphism.

Several studies have compared the morphometric characteristics of the transgender subjects and the control group in terms of gray and white matter models, which will be presented in the progress of the article. Although the number of studies evaluating these characteristics is not very high, they still make up the majority of the studies conducted in this sector. Probably one of the first studies on the anatomical differences between transgenders and the control group was conducted by the group of Emory, et al. In 1991, focusing on the corpus callosum, that is the structure made up of white matter that allows the interhemispheric connection. The corpus callosum or specific sub-components of this structure are thought to be involved in the process of sexual dimorphism concerning parameters such as shape and size, but the results appear contradictory. Emory, et al. Did not find significant differences in the form between the sexes or between the transgenders of both sexes compared to the control group made up of both men and women. To contradict this result, a study conducted by Yokota, et al. showed a difference between males and females, with an accuracy of about 74% when comparing the shape of the corpus callosum concerning the median sagittal plane. Using this measure, the value of the FtM and MtF transgenders was closer to their gender identity than their biological sex. The authors, therefore, suggested the usefulness of this measure as an objective criterion for the diagnosis of gender identity disorder. However, because their results are not individually applicable and have not been replicated, this proposal appeared absurd. Starting from these studies on the shape and size of the corpus callosum, other researchers have analyzed the morphometry of cerebral white matter in transgender individuals. Rametti, et al. Used a magnetic resonance instrument through which to build biomedical images, the so-called "diffusion tensor"; it is based on the directional movement of the water, which is, in turn, determined by the brain microstructure; it consists of a mathematical description of the size and direction (anisotropy) of the movement of the water molecules in a three-dimensional space designed to measure the diffusion of this molecule according to at least six gradient directions that allow an estimate of the diffusion tensor. Through this tool, the "Anisotropic diffusion" was evaluated: in the biological tissues organized the direction of diffusion is "forced" by the presence of cellular and extracellular structures, of which the myelinated fibers of the cerebral white matter play a fundamental role as they act as "guides" in which the water spreads. MtF transgender individuals who FtM on which the examination was performed had declared a certain sexual orientation and early-onset gender not conformity. The microstructural white matter patterns of MtF transgenders differed from the male and female control group in nearly all those fascicles showing sexual differences (upper longitudinal fasciculus, inferior frontal-occipital fasciculus, cingulum, and corticospinal tract).

Hence, the authors assume that some white matter fiber traits do not complete the masculinization process during the brain development of MtF transgenders. In the FtM transsexuals, the microstructural patterns of the white matter was more similar to that of the males, therefore to individuals who share their gender identity, compared to the female one they belong to. As with the male control group, the FtM transgenders showed a high anisotropic spread in different brain areas such as the longitudinal upper cingulate, minor forceps, and corticospinal tract, compared to the women in the control group. These fibers could therefore favor the masculinization process or not complete the feminization process. However, this study has a limitation, as the control group was made up of heterosexual people; therefore it is not clear to what extent the differences between the two groups reflect differences in sexual orientation rather than sexual identity.

The two brain structures that have been highlighted in the literature as implicated in sexual dimorphism and altered in transgender individuals include the central subdivision of the bed nucleus of the stria terminalis, BSTc and the third nucleus interstitial nucleus of the anterior hypothalamus, INAH3. Both of these two areas appear to be larger in men than women and contain more somatostatin neurons. Somatostatin is a polypeptide, originally isolated from the hypothalamus which inhibits the release of the pituitary growth hormone and also blocks the release of insulin and glucagon by the endocrine pancreas. The nucleus of the terminal stria bed is thought to be involved in the control of autonomic, behavioral, and neuroendocrine responses and closely connected to the amygdala, hippocampus, and medial prefrontal cortex. The third interstitial nucleus of the anterior hypothalamus is one of the four cell groups of the preoptic-anterior hypothalamic area and is involved in sexual and maternal behavior and for the secretion of gonadotropins. In transgenderism, these two structures seem to be involved in atypical sexual development, with the size and number of neurons more in synergy with what is desired by the subjects compared to biological sex. In MtF transgenders, the size and number of neurons in both brain areas resemble those of the female control group. This sexual reversal also appears to occur in FtM transgenders, but so far, there are too few data available. By these results, the altered number of neurons and the size of these areas could serve as markers for the atypical sexual differentiation of the brain in transsexuals; however the exact role played by these areas has yet to be well delineated. Concerning gray matter, a recent study by Simon, et al. Analyzed the volume of gray matter in both MtF and FtM transgenders and male and female control groups. Both categories of transgenders had a reduction in the volume of gray matter in some regions of the cerebellum (anterior lobe, left posterior, culmen, dentate nucleus, and slopes), left angular gyrus and lower left parietal lobe. The study, therefore, identified some regions where the gray matter volumes of transgender individuals resemble those of control subjects who have the same gender identity. In the lower and central right occipital convolutions, lingual and fusiform convolutions, and lower right temporal gyrus, the gray matter volumes were high in individuals with a female gender identity. In the pre-post central left convolutions,

left posterior cingulate, calcarine fissure, and pre-wedge, gray matter volumes were high in subjects with male gender identity. However, these results can only serve as ideas for new research in which there is greater control over the disturbance variables and the choice of samples constituting the control group. For these reasons, a direct relationship between volumetric changes of gray matter and aspects of transgender cannot yet be established exactly.

Sexual differences can also be observed in cortical thickness, regardless of differences in the brain and body size. An increase in cortical thickness in women compared to men was recorded in the parietal and frontal lobe, occipital, and temporal lobe. Considering this difference in cortical thickness between men and women, we could expect signs of feminization/masculinization in the context of research on transgenders. So far only two studies have compared brain thickness between untreated transgenders and control groups. Zubiarré-Elorza, et al. Measured cortical thickness in both MtF and FtM transgenders; the cortical thickness in MtF transgenders shows signs of feminization, with a greater thickness than the male control group and specifically in areas such as the orbitofrontal occipital region, island region and medial region. In the FtM transgenders, however, there were no signs of masculinization, but compared to the female control group, they had a greater cortical thickness in the parietal and temporal cortex. A study by Luders, et al. Supports the vision of feminized cortical thickness in MtF transgenders. They found greater cortical thickness of the left hemisphere, including the frontal orbit cortex, central frontal gyrus and orbital-frontal gyrus, and, in the right hemisphere, the parietal cortex, superior temporal sulcus, inferior temporal gyrus, fusiform gyrus, and lingual gyrus. The people in the male control group did not exhibit these characteristics, therefore the cortical thickness of MtF transgenders more closely resembled individuals with whom they shared their gender identity. Also in this case, the two studies differ as regards the sexual orientation of the participants, where in the first the transsexual sample appeared mixed and that of Zubiarré-Elorza was instead composed of exclusively homosexual transgenders.

In summary, the brains of the MtF and FtM transgenders do not seem to be completely masculinized or feminized. While, several structures typically attached to sexual dimorphism appear to be incompletely feminized / masculinized or incompletely masculinized/feminized.

In light of the present results it is therefore not possible to define precisely neuroanatomical markers for transgenderism. Available literature suggests that there are certainly neuroanatomical differences between transgenders and control groups, but these are, however, only detectable at the group level; therefore, the diagnosis currently needs to make use of psychiatric symptoms, rather than neuroanatomy.

A recent research, conducted by Prof. Gliske, confirms what has been said so far, therefore questions the currently most widespread interpretation of this disorder (and consequently its treatment) and claims that “gender dysphoria” is caused by an alteration in the activity of some networks of

brain connections and not by neuroanatomical anomalies. Starting from the first post-mortem analyzes of the brains of transsexual subjects, attention has focused on a specific nucleus of the hypothalamus called the bed of the terminal streak. The analyzes seemed to indicate that the size and shape of this brain region, which oversees the anxious response to the threats perceived by the person, could be reversed concerning biological sex. However, recent brain imaging studies have not supported this hypothesis. The new theory confirmed by this research, defined as “multisense”, focuses on the function of networks that connect different brain regions (instead of only on their dimensions and shapes). The researcher’s conclusion is that gender dysphoria would be a condition of perception, an alteration in the sense of gender influenced by associated reflexive behavioral responses, caused by an altered activity in three specific networks: that of distress, or negative stress, that of social behavior and that of the sense of body belonging.

Clinical treatments

Beyond how you want to see it, if a mental pathology or a condition of persistent malaise that in itself does not justify a diagnosis of mental disorder, gender dysphoria causes the person to be in a state of psychological suffering and functional impairment. The attention of health professionals must, therefore, be oriented towards these problems, both from a strictly medical and psychological point of view, especially with reference to the latest research showing an increase in anxiety and depressive disorders in the transgender population. Therefore, the normal and usual practice will provide for the addition of a psychological path to the clinical path, if the person wishes to face the transition to the new affirmation of sexual identity, to better favor the approach on psychoclinical manifestations eventually detected with respect to the case in question. The main objective of requesting help from the doctor is not to have psychological treatment but to obtain hormonal therapies and / or sex reassignment surgery, which bring their physical appearance closer to the gender identity they perceive; often it is the health professional who will indicate to the patient the importance of combining this treatment with psychological support. The combination of psychotherapy (which is never an obligation but a suggestion) and hormonal reassignment can be decisive in any case, especially when psychopathological symptoms are found.

Concerning the transition from male to female, feminizing hormones in moderate doses (e.g. transdermal estradiol patches 0.1–0.15 mg/day) associated with electrolysis, voice therapy, and other feminizing treatments may make changes to a more stable female gender role. Feminizing hormones also have important beneficial effects on the symptoms of gender dysphoria, often before there are visible changes in secondary sexual characteristics (e.g. breast growth, decreased growth of hair on the face and body, a redistribution of fat on the hips and the lower limbs). Feminizing hormones, even without psychological support or surgery, can make some patients feel sufficiently adequate as women, but psychological support therapy should never be underestimated. Surgery involves removing the penis and testicles and creating an artificial vagina. A part of the glans is maintained as a clitoris, which



is usually sexually sensitive and retains the ability to orgasm in most cases. The decision to undergo sexual reassignment surgery often raises important social problems for patients. Many of these patients are married and have children. A parent or spouse who changes sex and gender role is likely to experience significant adaptation problems for his or her most intimate relationships and is likely to lose loved ones during this process. From follow-up studies, genital surgery has helped some transsexuals live happier and more productive lives. It is therefore justified for highly motivated, appropriately assessed and treated transsexuals who have completed at least one year of real life in the opposite gender role. Participation in gender support groups, available in most major cities, is usually helpful.

Patients in the transition from female to male often require mastectomy early because it is difficult to live in the male role with abundant breast tissue; breast containment bandages often make breathing difficult. Also, hysterectomy and ovariectomy can be performed after a course of treatment with androgenic hormones (e.g. testosterone esters 300–400 mg intramuscular every three weeks or equivalent doses of androgenic transdermal patches or gels). Testosterone preparations deepen the voice permanently, induce a more “masculine” distribution of fat and muscles, induce clitoromegaly, and promote the growth of hair on the face and body. Patients can opt for one of the following options: a) an artificial phallus (neophallus) shaped by the skin transplanted from the inside of the forearm, leg, or abdomen (phalloplasty); b) a micropenis modeled from the fat tissue removed from the mount of Venus and placed around the hypertrophic clitoris for treatment with testosterone (metoidioplasty). With both procedures, scrotoplasty is usually also performed; the labia majora are sectioned to form empty cavities to approximate a scrotum, and the testicles are implanted to fill the newly formed scrotum. The anatomical results of surgical procedures for a neophallus are often less satisfactory, in terms of functionality and appearance than the procedures for new vaginas in cases of transgenders with the male-to-female transition, resulting in a relative decrease in requests for reassignment surgery of female-male genital sex.

Conclusions

It is therefore clear that, from the studies conducted so far, there are substantial elements to be able to assume that the neuroanatomophysiology of a dysphoric is different from a not-dysphoric person, but the studies have not yet clarified if it is these differences that cause the dysphoric condition or if the dysphoric condition shapes the anatomy and physiology of the brain by inducing the changes. It is logical and consequential to think, however, that the first solution is the most acceptable, and therefore certain anatomical-physiological alterations cause the person to perceive his identity status in a dysphoric way. In the future, studies are expected that children between the ages of two and six who already have the first dysphoric symptomatology to MRI and electroencephalogram every six months, following them up to adulthood, to understand if the anomalies represented are already present or not, and from that point begin to reason about the subject's sexual evolution.

References

- Altinay M, Anand A (2019) Neuroimaging gender dysphoria: a novel psychobiological model. *Brain Imaging Behav.* [Link: https://bit.ly/3gcEcNI](https://bit.ly/3gcEcNI)
- American Psychiatric Association (2013) Diagnostic and statistical manual of mental disorders (DSM-V), Ed 5.
- Atzil S, Hender T, Zagoory-Sharon O, Winetraub Y, Feldman R (2013) Synchrony and specificity in the maternal and the paternal brain: relations to oxytocin and vasopressin. *J Am Acad Child Adolesc Psychiatry* 51: 798-811. [Link: https://bit.ly/3844KgT](https://bit.ly/3844KgT)
- Bakker J, van Ophemert J, Slob AK (1993) Organization of partner preference and sexual behavior and its nocturnal rhythmicity in male rats. *Behav Neurosci* 107: 1049-1058. [Link: https://bit.ly/2NvMCTp](https://bit.ly/2NvMCTp)
- Bentz EK, Hefler LA, Kaufmann U, Huber JC, Kolbus A, et al. (2008) A polymorphism of the CYP17 gene related to sex steroid metabolism is associated with female-to-male but not male-to-female transsexualism. *Fertil. Steril* 90: 56-59. [Link: https://bit.ly/3hYzRPr](https://bit.ly/3hYzRPr)
- Berglund H, Lindström P, Savic I (2006) Brain response to putative pheromones in lesbian women. *Proc Natl Acad Sci U S A* 103: 8269-8274. [Link: https://bit.ly/31kT1sD](https://bit.ly/31kT1sD)
- Blanchard R (1993) The classification and labeling of nonhomosexual gender dysphorias. *Arch Sex Behav* 18: 315-334. [Link: https://bit.ly/2Nxmc3G](https://bit.ly/2Nxmc3G)
- Bockting WO, Miner MH, Swinburne RE, Hamilton A, Coleman E (2013) Stigma, mental health, and resilience in an online sample of the US transgender population. *Am J Public Health* 103 : 943–951. [Link: https://bit.ly/2NzZcAY](https://bit.ly/2NzZcAY)
- Breedlove SM, Nave G, Camerer CF, Schosser S, Vogt B, et al. (1995) Sexuality. Another important organ. *Nature* 378: 15-16. [Link: https://bit.ly/2B5licl](https://bit.ly/2B5licl)
- Brunnlieb C, et al. (2016) Vasopressin increases human risky cooperative behavior. *Proc Natl Acad Sci USA* 113: 2051-2056.
- Bunney BG, Li JZ, Walsh DM, Stein R, Vawter MP, et al. (2015) Circadian dysregulation of clock genes: clues to rapid treatments in major depressive disorder. *Mol Psychiatry* 20: 48-55. [Link: https://bit.ly/2BK7OCM](https://bit.ly/2BK7OCM)
- Burke SM, Manzouri AH, Savic I (2017) Structural connections in the brain in relation to gender identity and sexual orientation. *Sci Rep* 7: 17954. [Link: https://bit.ly/3eHEDyQ](https://bit.ly/3eHEDyQ)
- Burke SM, Manzouri AH, Dhejne C, Bergström K, Arver S, et al. (2018) Testosterone effects on the brain in transgender men. *Cereb Cortex* 28: 1582-1596. [Link: https://bit.ly/3i4BYRL](https://bit.ly/3i4BYRL)
- Burke SM, Majid DSA, Manzouri AH, Moody T, Feusner JD, et al. (2019) Sex differences in own and other body perception. *Hum Brain Mapp* 40: 474-488. [Link: https://bit.ly/3g4K2Qr](https://bit.ly/3g4K2Qr)
- Bychowski ME, Mena JD, Auger CJ (2013) Vasopressin infusion into the lateral septum of adult male rats rescues progesterone induced impairment in social recognition. *Neuroscience* 246: 52-58. [Link: https://bit.ly/380j8qm](https://bit.ly/380j8qm)
- Carlson JM, Greenberg T, Rubin D, Mujica-Parodi LR (2011) Feeling anxious: anticipatory amygdalo-insular response predicts the feeling of anxious anticipation. *Soc Cogn Affect Neurosci* 6: 74-81. [Link: https://bit.ly/2VldLwE](https://bit.ly/2VldLwE)
- Case LK, Brang D, Landazuri R, Viswanathan P, Ramachandran VS (2017) Altered white matter and sensory response to bodily sensation in female-to-male transgender individuals. *Arch Sex Behav* 46: 1223-1237. [Link: https://bit.ly/383lfJM](https://bit.ly/383lfJM)
- Chekroud AM, Ward EJ, Rosenberg MD, Holmes AJ (2016) Patterns in the human brain mosaic discriminate males from females. *Proc Natl Acad Sci U S A* 113: E1968. [Link: https://bit.ly/2BK7La4](https://bit.ly/2BK7La4)



19. Chen MC, Chiang WY, Yugay T, Patxot M, Özçivrit IB, et al. (2016) Anterior insula regulates multiscale temporal organization of sleep and wake activity. *J Biol Rhythms* 31: 182-193. [Link: https://bit.ly/3eEufb4](https://bit.ly/3eEufb4)
20. Collins KL, Guterstam A, Cronin J, Olson JD, Ehrsson HH, et al. (2017) Ownership of an artificial limb induced by electrical brain stimulation. *Proc Natl Acad Sci* 114: 166-171. [Link: https://bit.ly/3eAENIf](https://bit.ly/3eAENIf)
21. Drevets WC, Savitz J, Trimble M (2008) The subgenual anterior cingulate cortex in mood disorders. *CNS Spectr* 13: 663-681. [Link: https://bit.ly/2ZcKcOV](https://bit.ly/2ZcKcOV)
22. Drummond KD, Bradley SJ, Peterson-Badali M, Zucker KJ (2008) A follow-up study of girls with gender identity disorder. *Dev Psychol* 44: 34-45. [Link: https://bit.ly/3eNRI9T](https://bit.ly/3eNRI9T)
23. Emory LE, Williams DH, Cole CM, Amparo EG, Meyer WJ (1991) Anatomic variation of the corpus callosum in persons with gender dysphoria. *Arch Sex Behav* 20: 409-417. [Link: https://bit.ly/2VkjR0s](https://bit.ly/2VkjR0s)
24. Fernández R, Esteva I, Gómez-Gil E, Rumbo T, Almaraz M, et al. (2014) The (CA)_n polymorphism of ERβ gene is associated with FtM transsexualism. *J Sex Med* 11: 2986-2994. [Link: https://bit.ly/2A6evhP](https://bit.ly/2A6evhP)
25. Fernández R, Esteva I, Gómez-Gil E, Rumbo T, Almaraz M, et al. (2014) Association study of ERβ, AR, and CYP19A1 genes and MtF transsexualism. *J Sex Med* 11: 2986-2994. [Link: https://bit.ly/2BIB4JO](https://bit.ly/2BIB4JO)
26. Feusner JD, Dervic J, Kosidou K, Dhejne C, Bookheimer S, et al. (2016) Female-to-male transsexual individuals demonstrate different own body identification. *Arch Sex Behav* 45: 525-536. [Link: https://bit.ly/3i6aKdy](https://bit.ly/3i6aKdy)
27. Feusner JD, Lidström A, Moody TD, Dhejne C, Bookheimer SY, et al. (2017) Intrinsic network connectivity and own body perception in gender dysphoria. *Brain Imaging Behav* 11: 964-976. [Link: https://bit.ly/2VhINFB](https://bit.ly/2VhINFB)
28. Fisk NM (1974) Gender dysphoria syndrome—the conceptualization that liberalizes indications for total gender reorientation and implies a broadly based multi-dimensional rehabilitative regimen. *West J Med* 120: 386. [Link: https://bit.ly/2Yz3BKO](https://bit.ly/2Yz3BKO)
29. Garcia-Falgueras A, Swaab DF (2008) A sex difference in the hypothalamic uncinate nucleus: relationship to gender identity. *Brain* 131: 3132-3146. [Link: https://bit.ly/3g3vgtA](https://bit.ly/3g3vgtA)
30. Gómez-Gil E, Esteva I, Almaraz MC, Pasaro E, Segovia S, et al. (2010) Familiarity of gender identity disorder in non-twin siblings. *Arch Sex Behav* 39: 546-552. [Link: https://bit.ly/3eCbZiv](https://bit.ly/3eCbZiv)
31. Gliske SV (2019) A New Theory of Gender Dysphoria Incorporating the Distress, Social Behavioral, and Body-Ownership Networks. *eNeuro* 6. [Link: https://bit.ly/2VhW9BJ](https://bit.ly/2VhW9BJ)
32. Goodson JL, Kingsbury MA (2013) What's in a name? Considerations of homologies and nomenclature for vertebrate social behavior networks. *Horm Behav* 64: 103-112. [Link: https://bit.ly/31IGCFL](https://bit.ly/31IGCFL)
33. Gooren L (2006) The biology of human psychosexual differentiation. *Horm Behav* 50: 589-601. [Link: https://bit.ly/3eBJyBf](https://bit.ly/3eBJyBf)
34. Grivaz P, Blanke O, Serino A (2017) Common and distinct brain regions processing multisensory bodily signals for peripersonal space and body ownership. *Neuroimage* 147: 602-618. [Link: https://bit.ly/2VnDMM1](https://bit.ly/2VnDMM1)
35. Guillamon A, Junque C, Gómez-Gil E (2016) A review of the status of brain structure research in transsexualism. *Arch Sex Behav* 45: 1615-1648. [Link: https://bit.ly/2VnDFQB](https://bit.ly/2VnDFQB)
36. Guterstam A, Abdulkarim Z, Ehrsson HH (2015) Illusory ownership of an invisible body reduces autonomic and subjective social anxiety responses. *Sci Rep* 5: 9831. [Link: https://bit.ly/31j1A7t](https://bit.ly/31j1A7t)
37. Hare L, Bernard P, Sánchez FJ, Baird PN, Vilain E, et al. (2009) Androgen receptor repeat length polymorphism associated with male-to-female transsexualism. *Biol Psychiatry* 65: 93-96. [Link: https://bit.ly/3i1XNkR](https://bit.ly/3i1XNkR)
38. Heylens G, Elaut E, Kreukels BP, Paap MC, Cerwenka S, et al. (2014) Psychiatric characteristics in transsexual individuals: multicentre study in four European countries. *Br J Psychiatry* 204: 151-156. [Link: https://bit.ly/3i6cL9I](https://bit.ly/3i6cL9I)
39. Henningsson S, Westberg L, Nilsson S, Lindström B, Ekselius L, et al. (2005) Sex steroid-related genes and male-to-female transsexualism. *Psychoneuroendocrinology* 30: 657-664. [Link: https://bit.ly/38as4tm](https://bit.ly/38as4tm)
40. Hilti LM, Hänggi J, Vitacco DA, Kraemer B, Palla A, et al. (2013) The desire for healthy limb amputation: structural brain correlates and clinical features of xenomelia. *Brain* 136: 318-329. [Link: https://bit.ly/2NyMkeu](https://bit.ly/2NyMkeu)
41. Johnson ZV, Young LJ (2017) Oxytocin and vasopressin neural networks: implications for social behavioral diversity and translational neuroscience. *Neurosci Biobehav Rev* 76: 87-98. [Link: https://bit.ly/3eHAjQ8](https://bit.ly/3eHAjQ8)
42. Kettenis PT, Gooren L, Hannema SE, Meyer WJ, Murad MH, et al. (2017) Endocrine treatment of gender-dysphoric/gender-incongruent persons: an Endocrine Society clinical practice guideline. *J Clin Endocrinol Metab* 102: 3869-3903. [Link: https://bit.ly/382SSLN](https://bit.ly/382SSLN)
43. Kelly AM, Goodson JL (2014) Social functions of individual vasopressin-oxytocin cell groups in vertebrates: what do we really know? *Front Neuroendocrinol* 35: 512-529. [Link: https://bit.ly/3g3sSTE](https://bit.ly/3g3sSTE)
44. Kern L, Edmonds P, Perrin E, Stein M (2014) An 8-year-old biological female who identifies herself as a boy: perspectives in primary care and from a parent. *J Dev Behav Pediatr* 35: 301-303. [Link: https://bit.ly/2Z8NC5m](https://bit.ly/2Z8NC5m)
45. Kilpatrick LA, Holmberg M, Manzouri A, Savic I (2019) Cross sex hormone treatment is linked with a reversal of cerebral patterns associated with gender dysphoria to the baseline of cisgender controls. *Eur J Neurosci* 50: 3269-3281. [Link: https://bit.ly/3eDdehf](https://bit.ly/3eDdehf)
46. Kong J, Tu P, Zyloney C, Su T (2010) Intrinsic functional connectivity of the periaqueductal gray, a resting fMRI study. *Behav Brain Res* 211: 215-219. [Link: https://bit.ly/2Bcar06](https://bit.ly/2Bcar06)
47. Lebow M, Chen A (2016) Overshadowed by the amygdala: the bed nucleus of the stria terminalis emerges as key to psychiatric disorders. *Mol Psychiatry* 21: 450-463. [Link: https://go.nature.com/2B21FlN](https://go.nature.com/2B21FlN)
48. Lin CS, Ku HL, Chao HT, Tu PC, Li CT, et al. (2014) Neural network of body representation differs between transsexuals and cissexuals. *PLoS One* 9: e85914. [Link: https://bit.ly/3i0fJMV](https://bit.ly/3i0fJMV)
49. Luders E, Sánchez FJ, Tosun D, Shattuck DW, Gaser C, et al. (2012) Increased cortical thickness in male-to-female transsexualism. *J Behav Brain Sci* 2: 357-362. [Link: https://bit.ly/2VkcCuh](https://bit.ly/2VkcCuh)
50. Manzouri A, Savic I (2018) Cerebral sex dimorphism and sexual orientation. *Hum Brain Mapp* 39: 1175-1186. [Link: https://bit.ly/2ZqckVB](https://bit.ly/2ZqckVB)
51. Manzouri A, Savic I (2019) Possible neurobiological underpinnings of homosexuality and gender dysphoria. *Cereb Cortex* 29: 2084-2101. [Link: https://bit.ly/2NypeF2](https://bit.ly/2NypeF2)
52. Manzouri A, Kosidou K, Savic I (2017) Anatomical and functional findings in female-to-male transsexuals: testing a new hypothesis. *Cereb Cortex* 27: 998-1010. [Link: https://bit.ly/3eBtSh7](https://bit.ly/3eBtSh7)
53. McGeoch PD, Brang D, Song T, Lee RR, Huang M, et al. (2011) Xenomelia: A new right parietal lobe syndrome. *J Neurol Neurosurg Psychiatry* 82: 1314-1319. [Link: https://bit.ly/3dvRjHn](https://bit.ly/3dvRjHn)
54. Nawata H, Ogomori K, Tanaka M, Nishimura R, Urashima H, et al. (2010) Regional cerebral blood flow changes in female to male gender identity disorder. *Psychiatry Clin Neurosci* 64: 157-161. [Link: https://bit.ly/3g145zi](https://bit.ly/3g145zi)
55. Newman SW (2010) The medial extended amygdala in male reproductive behavior. A node in the mammalian social behavior network. *Ann N Y Acad Sci* 877: 242-257.



56. O'Connell LA, Hofmann HA (2011) The vertebrate mesolimbic reward system and social behavior network: a comparative synthesis. *J Comp Neurol* 519: 3599-3639. [Link: https://bit.ly/384zQ7Y](https://bit.ly/384zQ7Y)
57. Orozco-Solis R, Ramadori G, Coppari R, Sassone-Corsi P (2015) SIRT1 relays nutritional inputs to the circadian clock through the sf1 neurons of the ventromedial hypothalamus. *Endocrinology* 156: 2174-2184. [Link: https://bit.ly/2YzbVKy](https://bit.ly/2YzbVKy)
58. Orozco-Solis R, Aguilar-Arnal L, Murakami M, Peruquetti R, Ramadori G, et al. (2016) The circadian clock in the ventromedial hypothalamus controls cyclic energy expenditure. *Cell Metab* 23: 467-478. [Link: https://bit.ly/2CMxHSZ](https://bit.ly/2CMxHSZ)
59. Perrotta G (2019) *Psicologia generale*. Luxco ed. I ed.
60. Perrotta G (2019) *Psicologia dinamica*. Luxco ed. I ed.
61. Perrotta G (2019) *Psicologia clinica*. Luxco ed. I ed.
62. Perrotta G (2019) Post-traumatic stress disorder: Definition, contexts, neural correlations and cognitive-behavioral therapy. *J Pub Health Nutr* 2: 40-47. [Link: https://bit.ly/31f8vd](https://bit.ly/31f8vd)
63. Perrotta G (2019) Depressive disorders: Definitions, contexts, differential diagnosis, neural correlates and clinical strategies. *Peertechz Arch Depress Anxiety* 5: 009-033. [Link: https://bit.ly/3dGUXyw](https://bit.ly/3dGUXyw)
64. Perrotta G (2019) Behavioral addiction disorder: definition, classifications, clinical contexts, neural correlates and clinical strategies. *J Addict Behav* 2. [Link: https://bit.ly/2Z8QPSB](https://bit.ly/2Z8QPSB)
65. Perrotta G (2019) Paraphilic disorder: definition, contexts and clinical strategies. *Journal of Addiction Neuro Research* 1: 4. [Link: https://bit.ly/2Bbd1i9](https://bit.ly/2Bbd1i9)
66. Perrotta G (2019) Bipolar disorder: definition, differential diagnosis, clinical contexts and therapeutic approaches. *J Neurosci Neurological Surgery* 5. [Link: https://bit.ly/2BBJyCB](https://bit.ly/2BBJyCB)
67. Perrotta G (2019) Psychological trauma: definition, clinical contexts, neural correlates and therapeutic approaches. *Curr Res Psychiatry Brain Disord CRPBD-100006*.
68. Perrotta G (2019) Human mechanisms of psychological defence: definition, historical and psychodynamic contexts, classifications and clinical profiles. *Int J Neurorehabilitation* 7: 1. [Link: https://bit.ly/2B32PNx](https://bit.ly/2B32PNx)
69. Perrotta G (2020) Suicidal risk: definition, contexts, differential diagnosis, neural correlates and clinical strategies. *J Neuroscience Neurological Surgery* 6. [Link: https://bit.ly/3i8tc5o](https://bit.ly/3i8tc5o)
70. Perrotta G (2020) Oxytocin and the role of "regulator of emotions": definition, neurobiochemical and clinical contexts, practical applications and contraindications. *Arch Depress Anxiety* 6: 001-005. [Link: https://bit.ly/31ihtuN](https://bit.ly/31ihtuN)
71. Petkova VI, Ehrsson HH (2008) If I were you: perceptual illusion of body swapping. *PLoS One* 3: e3832. [Link: https://bit.ly/2CCP6NC](https://bit.ly/2CCP6NC)
72. Pierman S, Sica M, Allieri F, Viglietti-Panzica C, Panzica GC, et al. (2008) Activational effects of estradiol and dihydrotestosterone on social recognition and the arginine-vasopressin immunoreactive system in male mice lacking a functional aromatase gene. *Horm Behav* 54: 98-106. [Link: https://bit.ly/2CDNjb3](https://bit.ly/2CDNjb3)
73. Poepl TB, Langguth B, Rupprecht R, Laird AR, Eickhoff SB (2016) A neural circuit encoding sexual preference in humans. *Neurosci Biobehav Rev* 68: 530-536. [Link: https://bit.ly/38eIDWh](https://bit.ly/38eIDWh)
74. Preston C, Ehrsson HH (2016) Illusory obesity triggers body dissatisfaction responses in the insula and anterior cingulate cortex. *Cereb Cortex* 26: 4450-4460. [Link: https://bit.ly/3eBB8K8](https://bit.ly/3eBB8K8)
75. Rametti G, Carrillo B, Gómez-Gil E, Junque C, Segovia S, et al. (2011) White matter microstructure in female to male transsexuals before cross-sex hormonal treatment. A diffusion tensor imaging study. *J Psychiatr Res* 45: 199-204. [Link: https://bit.ly/2YAEB5X](https://bit.ly/2YAEB5X)
76. Ropar D, Greenfield K, Smith AD, Carey M, Newport R (2018) Body representation difficulties in children and adolescents with autism may be due to delayed development of visuo-tactile temporal binding. *Dev Cogn Neurosci* 29: 78-85. [Link: https://bit.ly/2VkcNwq](https://bit.ly/2VkcNwq)
77. Rosenblatt JD (2016) Multivariate revisit to "sex beyond the genitalia". *Proc Natl Acad Sci* 113: E1966-E1967. [Link: https://bit.ly/3fZr51D](https://bit.ly/3fZr51D)
78. Saper CB, Cano G, Scammell TE (2005) Homeostatic, circadian, and emotional regulation of sleep. *J Comp Neurol* 493: 92-98. [Link: https://bit.ly/2B2NbSk](https://bit.ly/2B2NbSk)
79. Saper CB, Scammell TE, Lu J (2005) Hypothalamic regulation of sleep and circadian rhythms. *Nature* 437: 1257-1263. [Link: https://bit.ly/31qc6cW](https://bit.ly/31qc6cW)
80. Savic I, Arver S (2011) Sex dimorphism of the brain in male-to-female transsexuals. *Cereb Cortex* 21: 2525-2533. [Link: https://bit.ly/2VkvMXr](https://bit.ly/2VkvMXr)
81. Savic I, Berglund H, Lindström P (2005) Brain response to putative pheromones in homosexual men. *Proc Natl Acad Sci* 102: 7356-7361. [Link: https://bit.ly/3eBZqng](https://bit.ly/3eBZqng)
82. Simon L, Kozák LR, Simon V, Czobor P, Unoka Z, et al. (2013) Regional grey matter structure differences between transsexuals and healthy controls – a voxel based morphometry study. *PLoS One* 8: e83947. [Link: https://bit.ly/2A4ZjI4](https://bit.ly/2A4ZjI4)
83. Smith ES, Junger J, Derntl B, Habel U (2015) The transsexual brain—a review of findings on the neural basis of transsexualism. *Neurosci Biobehav Rev* 59: 251-266. [Link: https://bit.ly/3eFSZzy](https://bit.ly/3eFSZzy)
84. Steensma TD, Biemond R, De Boer F, Cohen-Kettenis PT (2011) Desisting and persisting gender dysphoria after childhood: a qualitative follow-up study. *Clin Child Psychol Psychiatry* 16: 499-516. [Link: https://bit.ly/3dCw7zJ](https://bit.ly/3dCw7zJ)
85. Strang JF, Janssen A, Tishelman A, Leibowitz SF, Kenworthy L, et al. (2018) Revisiting the evidence of the rates of autism in studies of gender diverse individuals. *J Am Acad Child Adolesc Psychiatry* 57: 885-887. [Link: https://bit.ly/2Bfj2yW](https://bit.ly/2Bfj2yW)
86. Swaab DF, Hofman MA (1990) An enlarged suprachiasmatic nucleus in homosexual men. *Brain Res* 537: 141-148. [Link: https://bit.ly/2Vm3fFr](https://bit.ly/2Vm3fFr)
87. Swaab DF, Slob AK, Houtsmuller EJ, Brand T, Zhou JN (1995) Increased number of vasopressin neurons in the suprachiasmatic nucleus (SCN) of "bisexual" adult male rats following perinatal treatment with the aromatase blocker ATD. *Dev Brain Res* 85: 273-279. [Link: https://bit.ly/3dCdN9U](https://bit.ly/3dCdN9U)
88. Tillman RM, Stockbridge MD, Nacewicz BM, Torrisi S, Fox AS, et al. (2018) Intrinsic functional connectivity of the central extended amygdala. *Hum Brain Mapp* 39: 1291-1312. [Link: https://bit.ly/31vzDtp](https://bit.ly/31vzDtp)
89. Tsakiris M (2010) My body in the brain: a neurocognitive model of body-ownership. *Neuropsychologia* 48: 703-712. [Link: https://bit.ly/3dvqppz](https://bit.ly/3dvqppz)
90. Ujike H, Otani K, Nakatsuka M, Ishii K, Sasaki A, et al. (2009) Association study of gender identity disorder and sex hormone-related genes. *Prog Neuropsychopharmacol Biol Psychiatry* 33: 1241-1244. [Link: https://bit.ly/3g1I3he](https://bit.ly/3g1I3he)
91. Vasalou C, Henson MA (2010) A multiscale model to investigate circadian rhythmicity of pacemaker neurons in the suprachiasmatic nucleus. *PLoS Comput Biol* 6: e1000706. [Link: https://bit.ly/3dz9ZWP](https://bit.ly/3dz9ZWP)
92. Whitt JP, McNally BA, Meredith AL (2018) Differential contribution of Ca(2+) sources to day and night BK current activation in the circadian clock. *J Gen Physiol* 150: 259-275. [Link: https://bit.ly/2YyPONv](https://bit.ly/2YyPONv)
93. Yang F, Zhu X, Zhang Q, Sun N, Ji Y, et al. (2017) Genomic characteristics



of gender dysphoria patients and identification of rare mutations in RYR3 gene. *Sci Rep* 7: 8339. [Link: https://bit.ly/2YxcV1Q](https://bit.ly/2YxcV1Q)

94. Yokota Y, Kawamura Y, Kameya Y (2005) Callosal shapes at the midsagittal plane: MRI differences of normal males, normal females and GID. *Conf Proc IEEE Eng Med Biol Soc* 2005: 3055–3058. [Link: https://bit.ly/3hXykJg](https://bit.ly/3hXykJg)

95. Zavlin D, Wassersug RJ, Chegireddy V, Schaff J, Papadopulos NA (2019) Age-related differences for male-to-female transgender patients undergoing gender-affirming surgery. *Sex Med* 7: 86-93. [Link: https://bit.ly/2VkdrOR](https://bit.ly/2VkdrOR)

96. Zhou JN, Hofman MA, Gooren LJJ, Swaab DF (1995) A sex difference in the human brain and its relation to transsexuality. *Nature* 378: 68-70. [Link: https://bit.ly/3g1kuE8](https://bit.ly/3g1kuE8)

97. Zubiaurre-Elorza L, Junque C, Gómez-Gil E, Segovia S, Carrillo B, et al. (2013) Cortical thickness in untreated transsexuals. *Cereb Cortex* 23: 2855-2862. [Link: https://bit.ly/31kuJPO](https://bit.ly/31kuJPO)

Discover a bigger Impact and Visibility of your article publication with Peertechz Publications

Highlights

- ❖ Signatory publisher of ORCID
- ❖ Signatory Publisher of DORA (San Francisco Declaration on Research Assessment)
- ❖ Articles archived in worlds' renowned service providers such as Portico, CNKI, AGRIS, TDNet, Base (Bielefeld University Library), CrossRef, Scilit, J-Gate etc.
- ❖ Journals indexed in ICMJE, SHERPA/ROMEO, Google Scholar etc.
- ❖ OAI-PMH (Open Archives Initiative Protocol for Metadata Harvesting)
- ❖ Dedicated Editorial Board for every journal
- ❖ Accurate and rapid peer-review process
- ❖ Increased citations of published articles through promotions
- ❖ Reduced timeline for article publication

Submit your articles and experience a new surge in publication services
(<https://www.peertechz.com/submission>).

Peertechz journals wishes everlasting success in your every endeavours.

Copyright: © 2020 Perrotta G. This is an open-access article distributed under the terms of the Creative Commons Attribution License, which permits unrestricted use, distribution, and reproduction in any medium, provided the original author and source are credited.